ACVIM Consensus Statement
J Vet Intern Med 2010;24:10–26

Consensus Statements of the American College of Veterinary Internal Medicine (ACVIM) provide the veterinary community with up-to-date information on the pathophysiology, diagnosis, and treatment of clinically important animal diseases. The ACVIM Board of Regents oversees selection of relevant topics, identification of panel members with the expertise to draft the statements, and other aspects of assuring the integrity of the process. The statements are derived from evidence-based medicine whenever possible and the panel offers interpretive comments when such evidence is inadequate or contradictory. A draft is prepared by the panel, followed by solicitation of input by the ACVIM membership, which may be incorporated into the statement. It is then submitted to the Journal of Veterinary Internal Medicine, where it is edited prior publication. The authors are solely responsible for the content of the statements.

Endoscopic, Biopsy, and Histopathologic Guidelines for the Evaluation of Gastrointestinal Inflammation in Companion Animals

The WSAVA International Gastrointestinal Standardization Group: R.J. Washabau, M.J. Day, M.D. Willard, E.J. Hall, A.E. Jergens, J. Mansell, T. Minami, and T.W. Bilzer

Key words: Cat; Colon; Dog; Duodenum; Endoscopy; Histopathology; Intestine; Stomach.

Generation of the Guidelines

Diagnosis and treatment of companion animal gastrointestinal tract disorders have long been complicated by the absence of clinical, diagnostic, histopathologic, and therapeutic standards. Accordingly, the World Small Animal Veterinary Association (WSAVA) International Gastrointestinal (GI) Standardization Group was convened in 2004 for the purpose of developing standards for history taking, physical examination, laboratory diagnostic tests, imaging procedures and reports, endoscopic procedures and reports, biopsy procedures and reports, histopathologic interpretation, immunohistochemistry (IHC), treatment trials, and patient response and outcome in dogs and cats with gastrointestinal disease. The Standardization Group first met at the American College of Veterinary Internal Medicine (ACVIM) Forum in Minneapolis in 2004, and several abstracts of its work were presented at national and international meetings (WSAVA Congress, European College of Veterinary Internal Medicine [ECVIM] Congress, and ACVIM Forum). A final summary of Phase I studies was presented at the WSAVA Congress in Dublin in 2008. During Phase I (2004–2008), the GI Standardization Group published proposed standards for endoscopy,[1] biopsy,[2] and histopathological evaluation of inflammation[3] in endoscopic biopsies of the gastrointestinal tract of dogs and cats.

In 2008, the GI Standardization Group was invited to develop an ACVIM Consensus Statement on "Endoscopic, Biopsy, and Histopathologic Guidelines for the Evaluation of Gastrointestinal Inflammation in Companion Animals" for presentation at the 26th Annual ACVIM Forum in San Antonio, TX. After presentation at the ACVIM Forum, a written draft of the Consensus Statement was prepared by the Group and posted to the

Abbreviations:

ACVIM	American College of Veterinary Internal Medicine
CIBDAI	canine inflammatory bowel disease activity index
CRP	C-reactive protein
ECVIM	European College of Veterinary Internal Medicine
GMC	giant migrating contractions
HE	hematoxylin and eosin
IBD	inflammatory bowel disease
IEL	intraepithelial lymphocyte
IFN	interferon
IL	interleukin
IHC	immunohistochemistry
MHC	major histocompatibility complex
PCR	polymerase chain reaction
RT-PCR	reverse transcriptase polymerase chain reaction
TNF	tumor necrosis factor
WSAVA	World Small Animal Veterinary Association

From the Department of Veterinary Clinical Sciences, College of Veterinary Medicine, University of Minnesota, St Paul, MN (Washabau); the Division of Veterinary Pathology, Infection, and Immunity, School of Clinical Veterinary Science, University of Bristol, Langford, UK (Day); the Department of Small Animal Clinical Sciences, College of Veterinary Medicine, Texas A & M University, College Station, TX (Willard); the Division of Companion Animal Studies, School of Clinical Veterinary Science, University of Bristol, Langford, UK (Hall); the Department of Veterinary Clinical Sciences, College of Veterinary Medicine, Iowa State University, Ames, IA (Jergens); the Department of Pathobiology, College of Veterinary Medicine, Texas A & M University, College Station, TX (Mansell); HistoVet Inc., Kanagawa-ku, Yokohama, Japan (Minami); and the Institut fur Neuropathologie, Heinrich-Heine-Universitat Düsseldorf, Düsseldorf, Germany (Bilzer). A preliminary report was presented at the 2008 ACVIM Forum in San Antonio, TX.

Corresponding author: Dr Robert J. Washabau, VMD, PhD, Dipl. ACVIM, Department of Veterinary Clinical Sciences, College of Veterinary Medicine, University of Minnesota, 1352 Boyd Avenue, St Paul, MN 55108; e-mail: washabau@umn.edu.

Submitted May 31, 2009; Revised October 24, 2009; Accepted October 24, 2009.

Copyright © 2010 by the American College of Veterinary Internal Medicine

10.1111/j.1939-1676.2009.0443.x

ACVIM Website for additional commentary from the membership of the ACVIM Internal Medicine Specialty. The manuscript was further independently reviewed by a series of experts in the field. A revised manuscript was submitted to the ACVIM Board of Regents and editors of the *Journal of Veterinary Internal Medicine* for final review and approval.

An evidence-based medicine approach was used by the Group to develop the Consensus Statement. Where evidence was conflicting, ambiguous, or lacking, the Group adopted interpretive recommendations on the basis of its collective expertise.

Inflammatory Bowel Disease (IBD)—Scope of the Problem

IBD broadly refers to a group of idiopathic, chronic gastrointestinal disorders characterized by mucosal inflammation.[4,5] Although the prevalence of IBD is unknown, it is arguably the most common histopathologic diagnosis obtained in dogs and cats with chronic vomiting or diarrhea. Despite perceived importance, the accuracy of these diagnoses has been the subject of some contention. IBD may represent one or more forms of chronic enteropathy that are distinguished from food-responsive and antibiotic-associated causes by their therapeutic responsiveness to immunosuppressive agents but not to dietary or antibiotic therapy alone.[5] Although the underlying cause of IBD remains unknown, accumulating evidence in animal models suggests that intestinal inflammation results from altered interaction between gut microbes and the mucosal immune system in a susceptible host.[6–8] Aggressive host immune responses directed against bacteria or their products are believed to play a central role in the pathogenesis of chronic mucosal inflammation.[6] The concept of impaired immunoregulation in IBD is supported by observations of increased numbers of immunoglobulin-secreting plasma cells and T cells in inflamed tissues,[9–13] upregulated mucosal or luminal expression of nitric oxide metabolites,[5,14] and altered serum concentrations of selected acute phase proteins, such as C-reactive protein (CRP), in diseased dogs.[15,16] Genetic predispositions are recognized in several breeds, including Siamese cats, and German Shepherd Dogs, Basenjis, soft-coated Wheaten Terriers, and Shar Peis.[4,5,17]

Diagnosis of IBD currently is defined by (1) chronic (ie, $>$ 3 weeks) persistent or recurrent gastrointestinal signs; (2) histopathologic evidence of mucosal inflammation; (3) inability to document other causes of gastrointestinal inflammation; (4) inadequate response to dietary, antibiotic, and anthelmintic therapies alone; and (5) clinical response to anti-inflammatory or immunosuppressive agents. Clinical signs (eg, vomiting, small bowel diarrhea, large bowel diarrhea, weight loss, alterations in appetite) are attributed to mucosal cellular infiltrates, inflammatory mediators, and inflammation-associated enterocyte dysfunction and intestinal dysmotility.[4,5,18,19] Histopathologic evaluation of biopsy specimens is required for definitive diagnosis, but no standard microscopic grading system of IBD lesions has been universally accepted.

Limitations of Histopathology

Histopathologic examination is performed to distinguish normal from diseased tissue, characterize the nature and severity of tissue changes, and provide an accurate morphological or etiological diagnosis, thus facilitating formulation of prognosis and appropriate therapy. Some histopathological diagnoses (eg, adenocarcinoma) can be made relatively simply. By contrast, interpretation of mucosal inflammatory changes, and distinguishing them from alimentary lymphoma has proved to be far more complex. Characterization of gastrointestinal inflammation has been hampered by lack of accepted, standard criteria for measuring the histopathological changes within a sample of mucosal tissue.

Over the past 2 decades, several independent groups have developed and applied classification systems for characterizing the nature and severity of gastrointestinal inflammatory changes.[4,9–13,17,20–33] In most of these studies, the nature of gastrointestinal inflammation is portrayed primarily by the dominant population of inflammatory cells (eg, lymphoplasmacytic, eosinophilic, pyogranulomatous) within the lamina propria. Such populations, however, may overlap and occur in various combinations and patterns. In many instances, the morphologic or cytoarchitectural changes of the epithelium and mucosa have been inappropriately underemphasized. The severity of gastrointestinal inflammation usually has been graded by a simple 4-point scale (ie, normal, mild, moderate, marked or severe). Although this approach appears logical, the specific criteria defined by various groups have differed so that it is impossible to conclusively compare the histopathological changes described in different studies. Even when specific criteria are applied, substantial variation may occur among pathologists' interpretations of changes in gastrointestinal tissue samples. Willard et al,[34] for example, reported lack of uniformity in the assessment of 50% of biopsy samples examined by 5 veterinary pathologists. This interpretive variation poses problems for the routine diagnosis of gastrointestinal disease as well as for monitoring the progress of patients undergoing posttherapeutic endoscopy. Moreover, multicenter diagnostic and therapeutic clinical trials are not possible with such variation. With this background, a GI Standardization Group was convened with the support of the WSAVA, with the purpose of developing standards for the diagnosis and treatment of gastrointestinal diseases in the dog and cat. One of the 1st tasks of this group was to develop a consensus on the normal histology of the gastrointestinal tract with the subsequent aim of developing a set of histopathological standards for the nature and severity of mucosal inflammatory and associated morphological changes.

Normal Histology of the Gastrointestinal Tract

The normal histology of the canine and feline gastrointestinal tract is affected by variables such as developmental stage (eg, age of the animal,[35,36] dietary history, medication history) and therefore remains the subject of considerable controversy. Lack of agreement

19391676, 2010, 1, Downloaded from https://onlinelibrary.wiley.com/doi/10.1111/j.1939-1676.2009.0443.x, Wiley Online Library on [01/11/2025]. See the Terms and Conditions (https://onlinelibrary.wiley.com/terms-and-conditions) on Wiley Online Library for rules of use; OA articles are governed by the applicable Creative Commons License

on normal histology has been one reason for erroneous diagnosis of gastrointestinal inflammation in many veterinary patients. Lack of agreement on standards for normal histology also has limited universal acceptance of grading systems in the evaluation of IBD.

The GI Standardization Group used an evidence-based medicine approach[37] to establish a reference range for normal histologic findings in the gastrointestinal tract of dogs and cats. Several examples of Class II and III evidence-based data were found in the Group's review of the scientific literature. Most of the studies employed microscopic evaluation of hematoxylin and eosin (HE) stained tissues,[21–23,35–39] whereas others used IHC to label and count leukocyte populations.[11–13,40–48] Representative examples from the GI Standardization Group's archives have been published already,[3] but summaries of studies in each anatomic area follow.

Gastric Body Mucosa

Two studies have characterized the leukocyte subpopulations within the superficial region of the normal canine gastric fundic mucosa.[41,48] In one of these studies,[48] a "mucosal unit" was defined as a 250 μm length of mucosa, in which $CD3^+$ intraepithelial lymphocytes (IEL) (mean, 0.9; range, 0–2), $CD3^+$ lamina propria lymphocytes (mean, 4.2; range, 0.5–13), lamina propria eosinophils (mean, 0.5; range, 0–2), and lamina propria plasma cells (mean, 1.6; range, 0–5.8) were enumerated. Biopsy samples were derived from 8 dogs, in which considerable interanimal variation in cell counts was noted.

Gastric Antral Mucosa

The leukocyte subpopulations within the superficial region of the normal canine antral mucosa have been characterized in 2 studies.[41,48] In one of the studies,[48] a "mucosal unit" was defined as a 250-μm length of mucosa, in which $CD3^+$ IEL (mean, 4.4; range, 1.5–8), $CD3^+$ lamina propria lymphocytes (mean, 10.7; range, 2.5–16.5), lamina propria eosinophils (mean, 2.7; range, 0–6) and lamina propria plasma cells (mean, 6.8; range, 0.5–15.5) were enumerated. Biopsy samples were derived from 8 dogs in that study, in which considerable interanimal variation in cell counts was noted.

Duodenal Mucosa

Several studies have evaluated the normal canine and feline duodenal mucosa with HE and immunohistochemical staining.[43,47,49,50] The normal villus length for an adult dog is 722 ± 170 μm, the normal crypt depth is 1,279 ± 203 μm, and the normal villus to crypt ratio is 0.7 ± 0.3.[39,49,50] Normal dogs have a mean number of 3.6 ± 3.6 goblet cells per stretch of 100 villous enterocytes, and 9.3 ± 3.1 goblet cells per stretch of 100 cryptal enterocytes.[43] Villous IEL are less numerous in the dog (20.6 ± 9.5 per 100 enterocytes) than in the cat (47.8 ± 11.7 per 100 enterocytes), but the number of cryptal IEL in the dog (5.2 ± 2.3 per 100 enterocytes) is similar to that in the cat (4.6 ± 1.7 per 100 enterocytes).[43,47,50] In the dog, the total leukocyte count is greater in the cryptal lamina propria (156.3 ± 24.9 per 10,000 μm^2) than in the lamina propria of the base (128.3 ± 26.6 per 10,000 μm^2) or tip (100.7 ± 43.9 per 10,000 μm^2) of the villus.[43] Similarly, there are more eosinophils in the canine cryptal lamina propria (9.8 ± 7.5 per 10,000 μm^2) than in the lamina propria of the villus base (3.7 ± 3.5 per 10,000 μm^2) or tip (3.8 ± 6.1 per 10,000 μm^2).[43] In cats, a population of globular leukocytes sometimes is recognized within the intestinal epithelium. These cells have distinctive eosinophilic granules within the cytoplasm and express the molecule perforin as shown by IHC labeling with crossreactive antisera.[51] This observation suggests that the cells are granular lymphocytes with cytotoxic function. In general, these cells do not appear to increase in number in feline inflammatory enteropathy, but neoplasia of this lineage is documented.[46]

Colonic Mucosa

In the colonic mucosa, there are, on average, 7.7 ± 3.7 IEL per stretch of 100 colonocytes in the normal canine basal crypt epithelium.[43] In the lamina propria between the basal crypts of the canine colon there are approximately 5.5 ± 4.3 plasma cells and 3.8 ± 3.7 eosinophils per 10,000 μm^2.[20,43,44] Some studies have assessed the number of goblet cells in normal canine colonic cryptal epithelium (25.6 ± 7.3 per 100 colonocytes).[43,44,52] The GI Standardization Group recognized that measurement of goblet cells in colonic epithelium is not straightforward and that the number of such cells may be artifactually decreased by discharge of mucus during the biopsy process. For that reason, assessment of alteration in goblet cell number (specifically goblet cell hyperplasia) was not incorporated into the final version of the standard template.

Development of Standards for Diagnosis of Gastrointestinal Inflammation

The recognition and interpretation of inflammatory change in endoscopically derived biopsies of gastrointestinal tract mucosa historically has posed great challenges for veterinary pathologists. Fundamental questions in this diagnostic process include the following: (1) Are the biopsies of sufficient size and quality for accurate diagnosis? (2) What is the nature of the inflammatory response (eg, neutrophilic, eosinophilic, granulomatous, pyogranulomatous or lymphoplasmacytic)? (3) How severe is the inflammatory response? and (4) When may an inflammatory response be a precursor to lymphoid neoplasia?

Given these limitations in the microscopic examination of HE-stained sections, it has been suggested that IHC evaluation of mucosal biopsies might provide a more accurate means of assessing inflammation. When coupled with computer-aided morphometry (ie, counting numbers of cells of specific phenotypes per unit area of lamina propria or epithelium), subtle changes in cellular content may be identified in tissue that may not be regarded as abnormal on evaluation of HE-stained sections.[10] It is unlikely, however, that this time-consuming and costly procedure will become standard for routine clinical diagnosis.

19391676, 2010, 1, Downloaded from https://onlinelibrary.wiley.com/doi/10.1111/j.1939-1676.2009.0443.x, Wiley Online Library on [01/11/2025]. See the Terms and Conditions (https://onlinelibrary.wiley.com/terms-and-conditions) on Wiley Online Library for rules of use; OA articles are governed by the applicable Creative Commons License

Table 1. Morphologic and inflammatory changes typical of the canine gastric body mucosa.

Morphologic Criteria	Inflammatory Criteria
Surface epithelial injury	Intraepithelial lymphocytes
Gastric pit epithelial injury	Lamina propria lymphocytes/ plasma cells
Fibrosis/glandular nesting/mucosal atrophy	Lamina propria eosinophils
	Lamina propria neutrophils
	Gastric lymphofollicular hyperplasia

Table 3. Morphologic and inflammatory changes typical of the canine duodenal mucosa.

Morphologic Criteria	Inflammatory Criteria
Villus stunting	Intraepithelial lymphocytes
Epithelial injury	Lamina propria lymphocytes/ plasma cells
Crypt distension	Lamina propria eosinophils
Lacteal dilation	Lamina propria neutrophils
Mucosal fibrosis	

In response to these limitations, the GI Standardization Group developed guidelines for the standardized interpretation of inflammatory change in the gastrointestinal mucosa of the dog and cat.[3] These recently published guidelines provide a simple visual and textual description of the major inflammatory changes in the gastric body and antrum, duodenum and colon, and define what constitutes mild, moderate, and severe pathological change. The guidelines are applicable to tissues from both dogs and cats; the only distinction between the species being with respect to the numbers of duodenal IEL, which are greater in cats compared with dogs.[43,47] The guidelines are designed to be used "microscope-side" by veterinary pathologists and define changes at the level of the 40× microscope objective, which is considered to be the magnification at which most pathologists will refine their morphological diagnosis. Morphologic and inflammatory changes typical at each of the 4 anatomic sites are outlined in Tables 1–4.

The guidelines adopted by the GI Standardization Group are accompanied by a set of standard reporting forms, which encourage pathologists to evaluate biopsies and record findings in a consistent fashion (Appendices 1 and 2). The forms could serve as the basis for numerical scoring of inflammatory changes as would be undertaken in research investigations. Pathologists are encouraged to report the total number of tissue samples present on the microscope slide and document the quality of these samples using descriptions of "adequate," "marginal," and "inadequate" as defined by the GI Standardization Group.[2] If such information is not included in a biopsy report, the group recommends that clinicians specifically request that it be included in the final report. The importance of this request will be seen below when the effect of biopsy quality upon diagnosis is discussed ("Guidelines for Endoscopic Examination and Biopsy").

These histopathology guidelines have been presented to the clinical and research community for evaluation and the GI Standardization Group anticipates that they will be continually refined. The GI Standardization Group pathologists have used the guidelines to evaluate a large slide set, derived from both dogs and cats from 9 referral institutions in 6 different countries. The Group currently is using these guidelines to identify factors affecting interpathologist variation and histologic lesions associated with hypoalbuminemia. Although the interpretation of endoscopically obtained biopsies of gastrointestinal mucosa will remain a diagnostic challenge, acceptance and refinement of the GI Standardization Group's guidelines should help address current problems related to lack of standardization. Additional studies will be needed to evaluate the relative importance of each criterion and whether a weighted or nonweighted cumulative score is appropriate. The ultimate value of any grading system will be determined by its ability to accurately diagnose disease, direct therapy, and predict outcome.

Guidelines for Endoscopic Examination and Biopsy

Representative tissue samples containing lesions of interest are crucial for the diagnosis of most gastrointestinal tract diseases. There are 3 means of obtaining such biopsies: flexible endoscopy, laparoscopy, and surgery. Flexible endoscopy has 5 advantages. (1) Endoscopy permits the operator to see mucosal changes that cannot be visualized by the serosal approach of the surgeon. This in turn permits directed biopsy at these sites. (2) Endoscopy also permits the collection of multiple tissue biopsies (eg, 10 or more, if necessary) from each site, which is potentially important because some diseases may have a multifocal distribution, even within 1 section of the intestine. (3) In

Table 2. Morphologic and inflammatory changes typical of the canine antral mucosa.

Morphologic Criteria	Inflammatory Criteria
Surface epithelial injury	Intraepithelial lymphocytes
Gastric pit epithelial injury	Lamina propria lymphocytes/ plasma cells
Fibrosis/glandular nesting/mucosal atrophy	Lamina propria eosinophils
	Lamina propria neutrophils
	Gastric lymphofollicular hyperplasia

Table 4. Morphologic and inflammatory changes typical of the canine colonic mucosa.

Morphologic Criteria	Inflammatory Criteria
Surface epithelial injury	Lamina propria lymphocytes/ plasma cells
Crypt hyperplasia	Lamina propria eosinophils
Crypt dilation and distortion	Lamina propria neutrophils
Mucosal fibrosis and atrophy	Lamina propria macrophages

19391676, 2010, 1, Downloaded from https://onlinelibrary.wiley.com/doi/10.1111/j.1939-1676.2009.0443.x, Wiley Online Library on [01/11/2025]. See the Terms and Conditions (https://onlinelibrary.wiley.com/terms-and-conditions) on Wiley Online Library for rules of use; OA articles are governed by the applicable Creative Commons License

some instances, endoscopy permits diagnosis of selected lesions without the need for tissue biopsy (eg, ulceration, erosion, lymphangiectasia). (4) Endoscopic procedures have minimal risk of perforation and septic peritonitis, compared to surgical biopsy. (5) The procedure is quicker, less stressful, and less invasive to the patient, and may be less expensive than surgery.

Flexible endoscopy has some disadvantages. Standard duodenoscopy cannot access the entire gastrointestinal tract (although enteroscopy could), and duodenoscopy alone in animals with severe gastrointestinal tract disease might not permit detection of the most important lesions. It is very easy to obtain inadequate tissue samples (eg, mostly tips of villi) that do not readily permit diagnosis. Finally, even well-trained endoscopists cannot reliably sample duodenal muscularis mucosa or dense, submucosal infiltrative lesions with flexible endoscopic forceps.

Endoscopy is not necessarily appropriate for every animal with chronic gastrointestinal disease. It is impossible to make an all-encompassing list of when to do and when not to do gastrointestinal endoscopy. Substantial latitude must be given to the clinician who continually must weigh the specifics of the case, client expectations, monetary concerns, risk to the patient, and other factors. Nonetheless, certain general principles can be stated. First, endoscopy seldom benefits patients with acute diarrhea (ie, <3 weeks in duration) unless the disease is particularly severe or a specific disease needs to be quickly diagnosed or eliminated (eg, histiocytic ulcerative colitis, histoplasmosis, neoplasia). Second, clinical assessment usually seems more useful and appropriate than endoscopic biopsy in determining response of inflammatory diseases to therapy. Third, endoscopy is primarily of value in diagnosing infiltrative, erosive, or other anatomic (eg, lacteal dilatation, foreign body) problems. It seldom allows diagnosis of dietary-responsive enteropathy, antibiotic-responsive diarrhea, or gastrointestinal motility disorders. The healthier the patient (ie, modest to no weight loss, relatively good body condition score, normal serum albumin concentration, not lethargic, not anorexic, no ultrasonographic evidence of infiltrative disease), the more consideration should be given to therapeutic trials (eg, dietary, antibiotic, anthelmintic, or probiotic trials) instead of endoscopic biopsy, at least initially. Conversely, the more clinically ill the patient (eg, severe weight loss, very poor body condition score, hypoalbuminemia, anorexia, ultrasonographic evidence of infiltrative disease), the more reasonable it usually is to perform endoscopic biopsy before therapeutic trials. Fourth, if the clients allow, it is generally helpful to image the abdomen ultrasonographically before endoscopy in an attempt to ensure that infiltrative lesions out of reach of the endoscope (eg, mid-jejunum) are not present.

When endoscopy is performed, careful and thorough examination of the stomach, small intestine, and large intestine is the 1st step. Standardized endoscopic report forms have been developed that require a systematic, rigorous, and complete examination of the gastrointestinal tract. Good endoscopy forms have several features. They include patient identification and date, reason for procedure, specific equipment used (ie, endoscopes, biopsy forceps, foreign body retrieval devices, etc.), complications encountered, extent of examination (ie, how far the endoscope was advanced), generation of images, specific lesions, and final recommendations. Check boxes are strongly recommended in such report forms so as to document whether specific lesions were or were not seen and whether specific problems did or did not occur. They also are useful in helping to ensure that examinations are complete. Such forms, developed by the GI Standardization Group, have been endorsed by the Comparative Gastroenterology Society and the European Society for Comparative Gastroenterology, and are available at the WSAVA Website (http://www.wsava.org/StandardizationGroup.htm). Examples are included in Appendices 3 and 4 of this Consensus Statement.

Ileal biopsy is being recognized as potentially providing valuable information not always found in duodenal or colonic biopsies.[a,53,54] The endoscopist usually can obtain ileal biopsies (either by passing the endoscope into the ileum or blindly passing biopsy forceps through the ileo-colic valve) in dogs and cats. Serious consideration should be given to obtaining ileal biopsies in animals whenever gastroduodenoscopy or colonoscopy seems indicated, although the Group has yet to publish templates for ileal tissue.

Good tissue quality is as important as good endoscopic technique because poor-quality tissue samples may not be interpretable by microscopy. There are many objective studies and recommendations regarding optimal technique and technology for endoscopic biopsy of the human gastrointestinal tract,[55–59] but similar data are not as readily available for the dog and cat. Some generalizations may be made.[60–62] It seems intuitively obvious that larger (eg, 2.8 mm) biopsy forceps procure larger, and perhaps better quality, tissue samples than smaller (eg, 2.2 mm) forceps. That said, overall tissue quality seemingly depends upon mucosal thickness. Willard et al[63] reported that duodenal biopsy quality was equivalent between dogs and cats, despite the assumption that feline intestinal biopsies probably involved the use of smaller diameter endoscopes and biopsy forceps. The thinner feline duodenal mucosa may be more readily sampled, even into the muscularis mucosa, than the thicker canine duodenal mucosa.[63] This observation also may explain why the thinner ileal mucosa is more readily sampled than the thicker duodenal mucosa.

Variability in tissue quality may result from variability in sample submission technique as well as tissue processing in the diagnostic laboratory.[63] Therefore, tissue samples should be carefully removed from the biopsy forceps and submitted in such a manner as to avoid artifacts and to permit optimal tissue orientation in the laboratory. The clinician must communicate and work with the laboratory to assure proper tissue orientation on glass slides because the approach may vary from laboratory to laboratory. Techniques for handling and mounting tissue samples (see Table 5) have been described previously.[60,61] If samples are to be submitted free-floating in formalin, the only way to ensure they will be properly oriented is for the histopathology technician to examine each piece of tissue with a dissecting microscope as they are embedded.

19391676, 2010, 1, Downloaded from https://onlinelibrary.wiley.com/doi/10.1111/j.1939-1676.2009.0443.x, Wiley Online Library on [01/11/2025]. See the Terms and Conditions (https://onlinelibrary.wiley.com/terms-and-conditions) on Wiley Online Library for rules of use; OA articles are governed by the applicable Creative Commons License

Table 5. Basic principles used when submitting mounted intestinal tissue specimens (as opposed to floating freely).

- Retrieve and unfold tissue specimens from biopsy forceps using hypodermic needle, being careful not to induce artifacts by tearing or stretching the mucosa.
- Place biopsy specimens on nonabsorbent sponge or cellulose acetate paper and immediately orient tissue samples submucosal side down and villi up on sponge. This is only important for duodenal and ileal tissue samples. Up-down orientation is not important for gastric or colonic samples.
- Do not allow the samples to dry out before placing in formalin
- Place sponge and tissue biopsies in 10% buffered formalin. If the sponge or paper is placed directly into a vial of formalin, then the specimen side is typically oriented down. If the sponge is placed in a histopathology cassette, then the specimen side is placed up.

Substantially fewer biopsy samples are needed to establish a diagnosis as the quality of the tissue increases from inadequate to marginal to adequate,[2] although there are some important differences between the dog and the cat. Approximately 6 marginal or adequate tissue samples from the feline stomach or duodenum are sufficient to diagnose villus atrophy and mild to moderate cellular infiltration.[2] In the dog, however, approximately 6–7 adequate or 10–15 marginal gastric or duodenal tissue samples are required to reliably diagnose villus atrophy, lymphangiectasia, and mild or moderate cellular infiltrates.[2] Canine duodenal crypt lesions are seemingly more difficult to diagnose reliably, and approximately 13 adequate or 28 marginal samples may be required. The actual numbers probably will change as more studies evaluate this issue, but superior-quality samples enhance the diagnostic sensitivity of the biopsies. Therefore, the total number of tissue samples that should be taken during a procedure will depend upon the skill of the endoscopist. In general, skilled endoscopists must take fewer samples than less-skilled endoscopists to achieve the same number of adequate samples on the histology slide.[2]

The dependence of diagnosis on the quality of the tissue samples supports the notion that clinicians should insist upon pathology reports including both the total number of tissue samples submitted and the quality of these samples (ie, inadequate, marginal, adequate), to determine the level of confidence in the reported histological diagnosis (Figs 1–3). If most of the samples are inadequate or marginal, the clinician should reassess his or her technique for procedural error. If uncertain, the clinician could request a 2nd opinion on the slides to assess their quality.

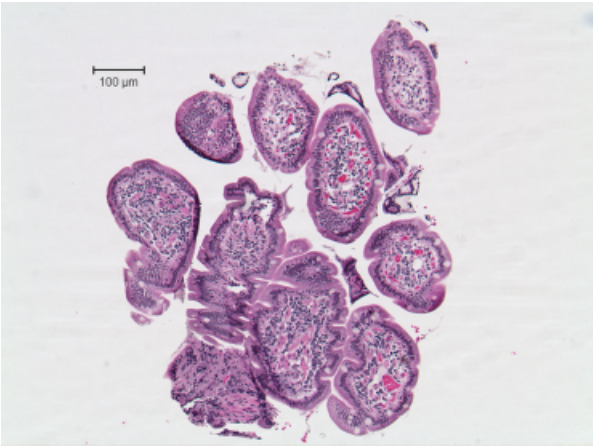

Fig 1. Photomicrograph of a biopsy sample of canine duodenum. Only villus tips are present. This is considered an "inadequate" tissue sample. Hematoxylin and eosin staining. Reprinted with permission.[2]

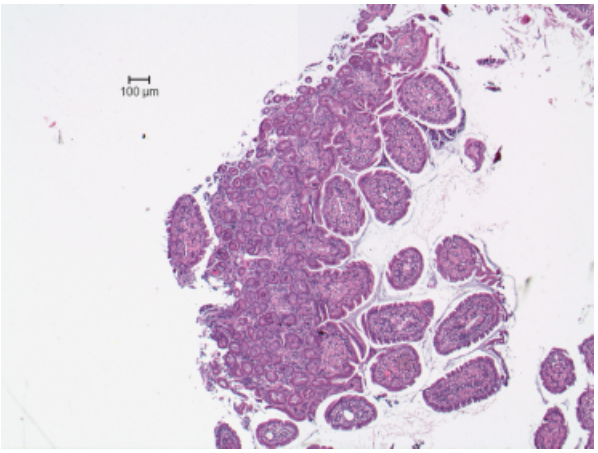

Fig 2. Photomicrograph of a biopsy sample of canine duodenum. This is an example of a "marginal" tissue sample. Hematoxylin and eosin staining. Reprinted with permission.[2]

Relationship between Histopathologic Change and Clinical Findings

The clinical course of IBD is characterized by chronicity and persistence or recurrence. Gastrointestinal signs are highly variable and may differ appreciably depending upon extent and anatomic localization of the disease. Several clinical indices have been developed to assess IBD activity in dogs including clinical signs,[4,5] histopathologic grades of mucosal inflammation,[4,20,40,64] phenotypic analysis of immune cells,[9–13,42] and measure-

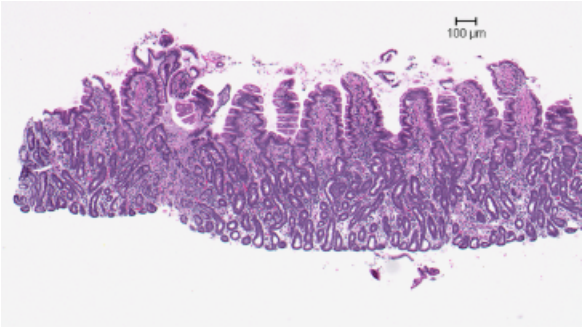

Fig 3. Photomicrograph of a biopsy sample of canine duodenum. This is an example of an "adequate" tissue sample that has at least 3 villi and encompasses the entire depth of the intestinal mucosa as seen by subvillus lamina propria, which extends to the mucosa-muscularis mucosa border. Even though muscularis mucosa is not present, the smooth, uniform lower border of the tissue sample shows that it extends to the muscularis mucosa. Hematoxylin and eosin staining. Reprinted with permission.[2]

19391676, 2010, 1, Downloaded from https://onlinelibrary.wiley.com/doi/10.1111/j.1939-1676.2009.0443.x, Wiley Online Library on [01/11/2025]. See the Terms and Conditions (https://onlinelibrary.wiley.com/terms-and-conditions) on Wiley Online Library for rules of use; OA articles are governed by the applicable Creative Commons License

ment of inflammatory mediators such as metabolites of nitric oxide,[14,b] acute phase reactant proteins such as serum CRP, and altered expression of cytokine mRNA transcripts[15,17,65] Similar comparative indices for use in the cat have been described only recently.[66]

Clinical indices remain the most widely used tools in assessing disease activity. A clinical scoring index (ie, Canine Inflammatory Bowel disease Activity Index [CIBDAI]) has been used to relate disease activity to histopathologic findings and serum CRP concentrations.[15] In that study, pretreatment clinical scores correlated best with a combination of histopathologic severity and CRP concentration at the time of diagnosis; posttreatment histopathologic assessment was not performed. In another study,[32] clinical signs and endoscopic lesions in dogs improved in nonhypoproteinemic dogs treated with prednisone and metronidazole, but treatment did not result in significant changes in the severity of gastric or duodenal histopathologic lesions. The relationship between histopathologic change and clinical findings has been equivocal or nonexistent in other studies. Allenspach et al[67] showed that total lymphocyte numbers in the duodenal mucosa of dogs with IBD did not change after clinically successful treatment with cyclosporine. Munster et al[30] failed to demonstrate a strong correlation between efficacy of therapy (reflected by CIBDAI score) and severity of histologic lesions. More recently, a prospective study evaluating 70 dogs with chronic enteropathy failed to show an association between severity of histologic changes (at diagnosis) and long-term outcome over 3 years.[32] Difficulties in showing associations in any of these studies may relate to the use of nonstandardized histologic scoring systems or differences in study design. The WSAVA GI Standardization Group has reported that one specific histologic change (ie, lacteal dilation) was associated with hypoalbuminemia.[68]

In summary, a review of the evidence currently available has not identified a strong association between clinical findings and histopathologic lesions in dogs with IBD, especially when posttreatment changes in disease activity are compared to posttreatment histopathologic findings. There is some evidence that dogs with moderate-to-severe IBD accompanied by increased CRP concentrations are more likely to have significant histologic lesions than dogs having only mild clinical signs,[15] and dogs with hypoalbuminemia are more likely to have certain histologic changes.[68] These findings underscore the fact that endoscopic biopsy is important to document inflammation (ie, 1 of the 4 criteria needed to diagnose IBD) but cannot be used by itself to diagnose or establish a prognosis in these patients. In cats with IBD, a recent report showed a positive correlation among morphologic changes (eg, epithelial alterations, villus fusion, atrophy), gastrointestinal signs, and upregulated expression of genes encoding some proinflammatory cytokines.[49]

An All-Encompassing Definition of Inflammatory Bowel Disease

Just as IBD cannot be diagnosed on the basis of histologic findings alone, neither should it be defined solely by those criteria. It should instead be defined using clinical, pathogenetic, imaging, pathophysiologic (eg, enterocyte function, immune responses, motility changes), and genetic criteria, in conjunction with histologic findings.[69]

Clinical Criteria

IBD currently is defined clinically as a spectrum of gastrointestinal disorders associated with idiopathic, chronic inflammation of the stomach, intestine, colon, or some combination of these organs.[3–5,15,20,25,69] A clinical diagnosis of IBD requires (1) chronic (ie, >3 weeks in duration) gastrointestinal signs (eg, anorexia, vomiting, weight loss, diarrhea, hematochezia, mucoid feces); (2) histopathologic evidence of mucosal inflammation; (3) inability to document other causes of gastroenterocolitis by thorough diagnostic evaluation; (4) inadequate response to appropriately designed and implemented therapeutic trials (ie, dietary, antibacterial, anthelmintic); and (5) clinical response to anti-inflammatory or immunosuppressive agents. Histopathologic changes in the absence of these criteria does not allow a diagnosis of IBD to be made.

Pathogenetic Criteria

Aggressive host immune responses directed against bacteria or their products are believed to play a central role in the pathogenesis of chronic mucosal inflammation.[6–8] The concept of impaired immunoregulation in IBD is supported by observations of increased numbers of immunoglobulin-secreting plasma cells and T cells in inflamed tissues,[9–13] upregulated mucosal or luminal expression of nitric oxide metabolites,[5,14] and altered serum concentrations of selected acute phase proteins, such as CRP, in diseased dogs.[15,16] Studies of cytokine gene expression profiles in dogs with chronic diarrhea have proven inconsistent, although altered cytokine profiles may be demonstrated in feline IBD. These inconsistencies may reflect that at present only mRNA encoding cytokines and not the actual cytokine molecules have been assayed. Although not yet investigated in companion animals, one additional component of inflammatory enteropathy in human patients and rodent models is failure of immune regulation normally provided by the IL-10 producing $CD4^+$ $CD25^+$ $foxp3^+$ natural T-regulatory cells. This population of cells is now characterized in both dogs and cats and a role for decreased immunoregulation in the pathogenesis of IBD in these species is predicted.

Imaging Criteria

Mucosal and submucosal thickening and luminal dilatation, but not loss of the normal layering, have been reported as ultrasound findings consistent with inflammation of the bowel. Ultrasound findings have been correlated with clinical signs in some studies,[25] but not others.[70,71] Mucosal echogenic changes have been proposed as having diagnostic relevance for food-responsive diarrhea and protein-losing enteropathies, but not for IBD.[71,72]

19391676, 2010, 1, Downloaded from https://onlinelibrary.wiley.com/doi/10.1111/j.1939-1676.2009.0443.x, Wiley Online Library on [01/11/2025]. See the Terms and Conditions (https://onlinelibrary.wiley.com/terms-and-conditions) on Wiley Online Library for rules of use; OA articles are governed by the applicable Creative Commons License

Pathophysiologic Criteria

IBD may be defined pathophysiologically in terms of changes in mucosal digestion and transport, blood flow, and motility. The clinical signs of IBD, whether small or large bowel, have long been attributed to the pathophysiology of malabsorption and hypersecretion, but experimental models of canine IBD have instead related clinical signs to the emergence of abnormal motility patterns. The pathophysiology of small intestinal IBD is explained by at least 2 interdependent mechanisms: the *mucosal immune response* and accompanying *changes in motility* (reviewed in Washabau and Holt[69]).

Immune Responses. A generic inflammatory response involving cellular elements (B- and T-lymphocytes, plasma cells, macrophages, and dendritic cells), secretomotor neurons (eg, vasoactive intestinal peptide, substance P, and cholinergic neurons), cytokines and interleukins (ILs), and inflammatory mediators (eg, leukotrienes, prostanoids, reactive oxygen metabolites, nitric oxide, 5-hydroxytryptamine, interferon [IFN]-γ, tumor necrosis factor [TNF]-α, and platelet-activating factor) is typical of canine and feline IBD.[11,14,17,42,43] There are many similarities between the inflammatory response of the small and large intestine, but recent immunologic studies suggest that IBD of the canine small intestine is a mixed T-helper type 1 (Th1)/Th2 response whereas IBD of the canine colon may be more of a Th1 type response with transcription of genes encoding IL-2, IL-12, INF-γ, and TNF-α.[69] Any discordance in such investigation may relate to the rapidly developing molecular technology with real-time reverse transcriptase polymerase chain reaction (RT-PCR) now largely replacing conventional gel-based techniques. In contrast to the dog, equivalent studies of feline intestinal inflammation have shown consistent alterations in cytokine gene expression.[51,73]

Motility Changes. Inflammation impairs motility by inducing changes in receptor, signal transduction, and ion channel activity in smooth muscle cells and enteric neurons.[18,19] Inflammation is associated with a shift in muscarinic receptor expression from M_3 to M_2 receptor subtype, impaired calcium mobilization, downregulation of L-type calcium channel expression, changes in the open-state probability of the large conductance calcium-activated potassium channels (K_{Ca}), downregulation of phospholipase A_2, and protein kinase C α, β, and ε isoenzymes, and activation of the transcription factor NF-κB in smooth muscle cells. Inflammation also sensitizes the colon to the stimulation of giant migrating contractions (GMCs) by the neurotransmitter substance P. Experimental studies in canine IBD[18,19] suggest that many of the clinical signs are correlated with changes in gastrointestinal motility (reviewed in Washabau and Holt[69]).

Genetic Criteria

IBD may be defined by *genetic* criteria in several species. Crohn's disease and ulcerative colitis are more common in certain human genotypes, and numerous genome-wide studies have now defined associations with genes including *NOD2* (nucleotide-binding oligomerization domain 2), *IL23R* (the IL-23 receptor gene), *IL12B* (the gene encoding the IL-12/23 p40 subunit), and *PTPN2* (the T-cell protein tyrosine phosphatase gene).[74] Genetic influences have not yet been identified in canine or feline IBD, but certain breeds (eg, Basenjis, Shar Peis, German Shepherd Dogs, Boxers, Rottweilers) appear to be at increased risk for the disease. With the ability to routinely evaluate the major histocompatibility complex (MHC) background or characterize single nucleotide polymorphisms by microarray, developments in canine genomics have yet to impact the study of IBD in this species. Many canine immune-mediated diseases have been shown to have MHC associations and the European LUPA initiative (http://www.eurolupa.org/public.html) will provide genome-wide analysis of selected canine disorders (excluding enteropathies). We predict that such investigations will be rewarding in understanding the basis of canine IBD, but will require tightly phenotyped case material. The accumulation of such cases will first necessitate the acceptance of standards in diagnosis as proposed by this Consensus Statement.

Distinguishing Lymphoplasmacytic Inflammation from Lymphoma

There is mounting evidence that chronic mucosal lymphoplasmacytic inflammation may be a precursor to the development of alimentary lymphoma in humans, dogs, and cats. This phenomenon is documented in human celiac patients[75] and in human patients and cats with *Helicobacter*-associated gastric mucosa-associated lymphoid tissue lymphoma.[76] There is less conclusive evidence for lymphomagenesis occurring during ulcerative colitis and Crohn's disease in humans, in which immunomodulatory therapy, rather than disease per se, may trigger malignant transformation of mucosal lymphocytes.[77] For many years, it also has been proposed that canine and feline inflammatory bowel disease may transform into alimentary lymphoma and one of the greatest challenges for veterinary pathologists is sometimes differentiating between a chronic mononuclear inflammatory process and lymphoid neoplasia.

This distinction is a major issue in feline medicine where alimentary lymphoma is now the most common clinical presentation of this tumor.[78] Two distinct histopathological variants of feline alimentary lymphoma are recognized: (1) small cell lymphocytic villus lymphoma, which is a T-cell tumor that arises at the base of the villus in older cats, and (2) large cell lymphoblastic lymphoma, which affects cats of any age and is a more aggressive and potentially metastatic disease. The most difficult distinction for the pathologist is between chronic inflammation and emergent small cell lymphocytic villus lymphoma. Although these lesions may be relatively lymphocytic (as opposed to lymphoplasmacytic) and there may be degrees of epitheliotropism, it often is not possible to make a definitive diagnosis on the basis of microscopy of HE-stained sections alone.

When routine histopathology is insufficient to differentiate small cell lymphoma from lymphocytic-plasmacytic enteritis, 2 newer diagnostic modalities have

19391676, 2010, 1, Downloaded from https://onlinelibrary.wiley.com/doi/10.1111/j.1939-1676.2009.0443.x, Wiley Online Library on [01/11/2025]. See the Terms and Conditions (https://onlinelibrary.wiley.com/terms-and-conditions) on Wiley Online Library for rules of use; OA articles are governed by the applicable Creative Commons License

simplified the task of discriminating between IBD and alimentary lymphoma in the cat. Immunophenotyping for expression of CD3 and CD79a gives a clear impression of the lineage of the infiltrating population in many cases.[79] A recent retrospective immunohistochemical study of 32 cats with an initial histopathological diagnosis of alimentary lymphoma suggested that in 5 cases the more appropriate diagnosis would have been IBD.[80] The 2nd approach to distinguishing between inflammatory and neoplastic infiltration is clonality testing by polymerase chain reaction (PCR) to identify rearrangements in the T-cell receptor γ chain gene (*TCRG*). In the 1st such study, a polyclonal population of T cells was confirmed in the intestine of all 9 cats with IBD, but clonal rearrangement was identified in 22/28 cats with alimentary T-cell lymphoma.[81] Clonality testing remains a useful adjunct to histopathological and immunohistochemical evaluation, with the authors of the manuscript emphasizing that IHC retains precedence over clonality testing as a diagnostic procedure. Both procedures (IHC and clonality testing) may be performed on paraffin wax-embedded tissue, and the clinician need only collect a single set of biopsies for diagnostic purposes. These preliminary studies require wider corroboration and it is the intention of the WSAVA GI Standardization Group to address this issue in the future.

Distinguishing *Helicobacter*-Associated Gastritis from Gastritis Associated with IBD

Gastritis is a common cause of chronic vomiting that may be associated with IBD, dietary indiscretion, foreign body and toxin ingestion, nonsteroidal anti-inflammatory drug usage, metabolic disease (eg, renal and hepatobiliary disease), and gastric (viral, bacterial, protozoal, fungal, and helminth) infection.[82] Although the mucosal inflammation of IBD principally involves the small and large intestines, chronic gastritis may be observed as a component of IBD in these same patients.[82,83]

The association of *Helicobacter* spp. infection with chronic gastritis in dogs and cats has been the subject of considerable investigation and debate (summarized in Neiger and Simpson[84]). The 2000 ACVIM Consensus Statement[85] on *Helicobacter*-associated gastritis concluded that (1) *Helicobacter* spp. are highly prevalent in healthy and sick dogs and cats, (2) a direct casual relationship among *Helicobacter* spp., gastritis, and clinical signs has not been firmly established, and (3) *Helicobacter* spp.-associated gastritis is variable in its severity and characterized by a lymphoplasmacytic infiltrate in the lamina propria, lymphoid follicular hyperplasia, and *Helicobacter* organisms colonized within gastric glands. The dual presence of biopsy-proven gastric inflammation accompanied by mucosal invasion with *Helicobacter* organisms, diagnosed by special stains (Warthin-Starry), PCR, or fluorescence in situ hybridization, may serve to differentiate *Helicobacter* gastritis from IBD involving the gastric mucosa.[86] Because of the gastric carriage of *Helicobacter* spp. in both health and disease, the GI Standardization Group has concluded that it may not be possible to differentiate IBD-associated gastritis from *Helicobacter*-associated gastritis by histopathologic examination of HE-stained sections.

Conclusions

To achieve a consensus on the endoscopic and histopathologic evaluation of gastrointestinal inflammation in the dog and cat, the GI Standardization Group recommends the following:

(a) Intestinal biopsy is not appropriate in every animal with chronic gastrointestinal disease. Where biopsy is indicated, endoscopic biopsy is the preferred choice.[87] Endoscopy is primarily of value when looking for infiltrative, erosive or other anatomic problems. Well-designed therapeutic trials generally are more effective in diagnosing dietary-responsive and antibiotic-responsive causes of diarrhea. Severe weight loss, poor body condition, severe anorexia, hypoalbuminemia, ultrasonographic evidence of substantial infiltrative disease, or some combination of these generally indicates that endoscopy is appropriate earlier in the diagnostic evaluation as opposed to after therapeutic trials. When endoscopy is indicated, biopsy of the ileum ideally should be performed in addition to gastroduodenoscopy and colonoscopy.

(b) Clinicians should use the clinical and histopathologic criteria outlined in "An All-Encompassing Definition of Inflammatory Bowel Disease" to diagnose IBD, recognizing that IBD is not solely a histopathologic diagnosis. Carefully designed and appropriately implemented therapeutic trials for dietary-responsive and antibiotic-responsive disease must be performed before IBD can be diagnosed.

(c) Clinicians performing gastrointestinal endoscopy should routinely use standard report forms (either those developed by the WSAVA or report forms with similar information and requirements) not only to document what was achieved, but also to ensure complete and reliable endoscopic examinations.[1]

(d) Clinicians should ask that pathology reports include assessment of quantity and quality of tissue samples (ie, inadequate, marginal, or adequate, as defined by the WSAVA GI Standardization Group[2]) to allow the clinician to gauge the confidence placed in the histologic interpretation.

(e) Clinicians should ask pathologists to evaluate endoscopic gastric and intestinal tissue samples using a standardized classification system, for example, the one proposed by the WSAVA GI Standardization Group[3] or some other reference standard. Universal usage of one system would enhance the ability of clinicians and specialists to meaningfully consult on cases and critically evaluate studies. A caveat with any classification system is that it will evolve over time and be refined as has happened with other gastrointestinal classification systems.[88–91]

(f) Clinicians must recognize that differences in tissue processing and staining can make it difficult to identify neutrophils and eosinophils. Hence, a pathologist at one laboratory may have difficulty in evaluating

19391676, 2010, 1, Downloaded from https://onlinelibrary.wiley.com/doi/10.1111/j.1939-1676.2009.0443.x, Wiley Online Library on [01/11/2025]. See the Terms and Conditions (https://onlinelibrary.wiley.com/terms-and-conditions) on Wiley Online Library for rules of use; OA articles are governed by the applicable Creative Commons License

these cells on slides that originate from a different laboratory.[68,c]

Results presented in our previous work[3] and the work of many previous investigators represent an attempt to create an international histopathological standard for the characterization of inflammatory and other associated morphological abnormalities of the stomach, intestine, and colon of dogs and cats. The WSAVA GI Standardization Group developed the model in the hope that it would be critically evaluated by peers and, if adopted as an international standard, used to define inflammatory changes in the canine and feline gastrointestinal tract. The Group recognizes that simply producing a template does not mean that its availability will immediately address all of the current problems related to the microscopic interpretation of endoscopic biopsy samples. The Group encourages testing and refinement of the model in retrospective and prospective studies. Indeed, the Group has used this model to report factors affecting interpathologist variation[c] and histologic lesions associated with hypoalbuminemia.[68] Templates and reporting forms described here and reported previously[3] have been designed to have ready applicability to retrospective or prospective research investigations, in which a numerical histopathological score may be correlated with clinical or therapeutic outcome variables. The simple numerical addition of grades of histopathological change (where normal = 0, mild = 1, moderate = 2, and marked = 3) may provide an overall histological score for the tissue of interest. Over time, some refinement in the model will be necessary and appropriate. In that regard, weighted grading systems may be needed to differentiate the importance of various lesions (eg, crypts versus villi versus lacteals versus lamina propria cellularity). Validation of any classification system will require well-designed studies, well-represented patient populations, and adequate follow-up. Studies with small numbers of animals or studies of relatively uncommon diseases may yield skewed results and render interpretation difficult or meaningless. The effort will require years of work, even when multiple institutions coordinate their efforts. Until that time, use of standardized terminology should prove helpful.

The WSAVA GI Standardization Group hopes that the availability of these template documents will prove of value to clinicians and pathologists working in the field of canine and feline gastroenterology and will facilitate the reporting of microscopic changes in biopsy samples, reducing variation among the interpretations of different pathologists and, consequently, among different published studies.

Acknowledgments

The members of the GI Standardization Group gratefully acknowledge the financial sponsorship of Hill's Pet Nutrition. No member of the Group has declared having personal or research funding from Hill's Pet Nutrition. The group also acknowledges the support and encouragement of the WSAVA Executive Board and Scientific Advisory Committee. The GI Standardization Group thanks Drs Marge Chandler, Jody Gookin, Michael Leib, Stanley Marks, Kenneth Simpson, and David Twedt for their thoughtful critiques of the manuscript. The work of the WSAVA Gastrointestinal Standardization Group was funded by Hill's Pet Nutrition under the auspices of the World Small Animal Veterinary Association.

Footnotes

[a] Dossin O, Tesseydre JF, Concordet D, et al. Is duodenal mucosa representative of other small intestinal parts in inflammatory bowel disease affected dogs? J Vet Intern Med 2007;21:613 (abstract)

[b] Jergens AE, Carpenter SL, Wannemuehler Y, et al. Molecular detection of inducible nitric oxide synthase in canine inflammatory bowel disease. J Vet Intern Med 1998; 12:205 (abstract)

[c] Willard MD, Mansell J, Moore G, et al. Correlation between pathologists assessing endoscopic gastric and intestinal biopsies using WSAVA guidelines: A report from the World Small Animal Veterinary Association Gastrointestinal Standardization Group. J Vet Inter Med 2008;22:1456 (abstract)

References

1. Gastrointestinal Endoscopy Standards. Available at: http://www.wsava.org/standardizationgroup.htm. Accessed June 2007.

2. Willard MD, Mansell J, Fosgate GT, et al. Effect of sample quality on the sensitivity of endoscopic biopsy for detecting gastric and duodenal lesions in dogs and cats. J Vet Intern Med 2008; 22:1084–1089.

3. Day MJ, Bilzer T, Mansell J, et al. Histopathological standards for the diagnosis of gastrointestinal inflammation in endoscopic biopsy samples from the dog and cat: A report from the World Small Animal Veterinary Association Gastrointestinal Standardization Group. J Comp Path 2008;137:S1–S43.

4. Jergens AE, Moore FM, Haynes JS, et al. Idiopathic inflammatory bowel disease in dogs and cats: 84 cases (1987–1990). J Am Vet Med Assoc 1992;201:1603–1608.

5. Jergens AE. Inflammatory bowel disease: Current perspectives. Vet Clin North Am Small Anim Pract 1999;29:501–521.

6. Chichkowski M, Hale LP. Bacterial-mucosal interactions in inflammatory bowel disease. Am J Physiol Gastrointest Liver Physiol 2008;295:G1139–G1149.

7. Xavier RJ, Podolsky DK. Unravelling the pathogenesis of inflammatory bowel disease. Nature 2007;448:427–434.

8. Sartor RB. Mechanisms of disease: Pathogenesis of Crohn's disease and ulcerative colitis. Nat Clin Pract Gastroenterol Hepatol 2006;3:390–407.

9. Waly NE, Stokes CR, Gruffydd-Jones TJ, et al. Immune cell populations in the duodenal mucosa of cats with inflammatory bowel disease. J Vet Intern Med 2004;18:816–825.

10. German AJ, Hall EJ, Day MJ. Immune cell populations within the duodenal mucosa of dogs with enteropathies. J Vet Intern Med 2001;15:14–25.

11. Jergens AE, Moore FM, Kaiser MS, et al. Morphometric evaluation of immunoglobulin A-containing and immunoglobulin G-containing cells and T cells in duodenal mucosa from healthy dogs and from dogs with inflammatory bowel disease or nonspecific gastroenteritis. Am J Vet Res 1996;57:697–704.

12. Jergens AE, Gamet Y, Moore FM, et al. Colonic lymphocyte and plasma cell populations in canine lymphocytic-plasmacytic colitis: An immunohistochemical and morphometric study. Am J Vet Res 1999;60:515–520.

19391676, 2010, 1, Downloaded from https://onlinelibrary.wiley.com/doi/10.1111/j.1939-1676.2009.0443.x, Wiley Online Library on [01/11/2025]. See the Terms and Conditions (https://onlinelibrary.wiley.com/terms-and-conditions) on Wiley Online Library for rules of use; OA articles are governed by the applicable Creative Commons License

13. Stonehewer J, Simpson JW, Else RW, et al. Evaluation of B and T lymphocytes and plasma cells in colonic mucosa from healthy dogs and dogs with inflammatory bowel disease. Res Vet Sci 1998;65:59–63.

14. Gunawardana SC, Jergens AE, Ahrens FA, et al. Colonic nitrite and immunoglobulin G concentrations in dogs with inflammatory bowel disease. J Am Vet Med Assoc 1997;211:318–321.

15. Jergens AE, Schreiner CA, Frank DE, et al. A scoring index for disease activity in canine inflammatory bowel disease. J Vet Intern Med 2003;17:291–297.

16. McCann TM, Ridyard AE, Else RW, et al. Evaluation of disease activity markers in dogs with idiopathic inflammatory bowel disease. J Small Anim Pract 2007;48:620–625.

17. German AJ, Helps CR, Hall EJ, et al. Cytokine mRNA expression in mucosal biopsies from German Shepherd dogs with small intestinal enteropathies. Dig Dis Sci 2000;45:7–17.

18. Sethi AK, Sarna SK. Colonic motor activity in acute colitis in conscious dogs. Gastroenterology 1991;100:954–963.

19. Jouet P, Sarna SK, Singaram C, et al. Immunocytes and abnormal gastrointestinal motor activity during ileitis in dogs. Am J Physiol 1995;269:G913–G924.

20. Wilcock B. Endoscopic biopsy interpretation in canine and feline enterocolitis. Semin Vet Med Surg 1992;7:162–171.

21. Spinato MT, Barker IK, Houston DM. A morphometric study of the canine colon: Comparison of control dogs and cases of colonic disease. Can J Vet Res 1990;54:477–485.

22. Roth L, Walton AM, Leib MS, Burrows CF. A grading system for lymphocytic plasmacytic colitis in dogs. J Vet Diagn Investig 1990;2:257–262.

23. Hart JR, Shaker E, Patnaik AK, Garvey MS. Lymphocytic-plasmacytic enterocolitis in cats: 60 cases (1988–1990). J Am Anim Hosp Assoc 1994;30:505–514.

24. Yamasaki K, Suematsu H, Takahashi T. Comparison of gastric and duodenal lesions in dogs and cats with and without lymphocytic-plasmacytic enteritis. J Am Vet Med Assoc 1996;209:93–97.

25. Baez JL, Hendrick MJ, Walker LM, Washabau RJ. Radiographic, ultrasonographic, and endoscopic findings in cats with inflammatory bowel disease of the stomach and small intestine: 33 cases (1990–1997). J Am Vet Med Assoc 1999;215:349–354.

26. Kull PA, Hess RS, Craig LE, et al. Clinical, clinicopathologic, radiographic, and ultrasonographic characteristics of intestinal lymphangiectasia in dogs: 17 cases (1996–1998). J Am Vet Med Assoc 2001;219:197–202.

27. Zentek J, Hall EJ, German AJ, et al. Morphology and immunopathology of the small and large intestine in dogs with non-specific dietary sensitivity. J Nutr 2002;132:1652S–1654S.

28. Peters IR, Helps CR, Calvert EL, et al. Cytokine mRNA quantification in duodenal mucosa from dogs with chronic enteropathies by real-time reverse transcriptase polymerase chain reaction. J Vet Intern Med 2005;19:644–653.

29. Wiinberg B, Spohr A, Dietz HH, et al. Quantitative analysis of inflammatory and immune responses in dogs with gastritis and their relationship to *Helicobacter* spp. infection. J Vet Intern Med 2005;19:4–14.

30. Münster M, Hörauf A, Bilzer T. Assessment of disease severity and outcome of dietary, antibiotic, and immunosuppressive interventions by use of the canine IBD activity index in 21 dogs with inflammatory bowel disease. Berl Münch Tierärztl Wochenschr (Berlin) 2006;119:493–505.

31. Allenspach K, Wieland B, Gröne A, Gaschen F. Chronic enteropathies in dogs: Evaluation of risk factors for negative outcome. J Vet Intern Med 2007;21:700–708.

32. Garcia-Sancho M, Rodriguez-Franco F, Sainz A, et al. Evaluation of clinical, macroscopic, and histopathologic response to treatment in nonhypoproteinemic dogs with lympho-plasmacytic enteritis. J Vet Intern Med 2007;21:11–17.

33. Brandtzaeg P, Kiyono H, Pabst R, et al. Terminology: Nomenclature of mucosa-associated lymphoid tissue. Mucos Immunol 2008;1:31–37.

34. Willard MD, Jergens AE, Duncan RB, et al. Interobserver variation among histopathologic evaluations of intestinal tissues from dogs and cats. J Am Vet Med Assoc 2002;220:1177–1182.

35. Baum B, Meneses F, Kleinschmidt S, et al. Age-related histomorphologic changes in the canine gastrointestinal tract: A histologic and immunohistologic study. World J Gastro 2007; 13:152–157.

36. Kleinschmidt S, Meneses F, Nolte I, et al. Distribution of mast cell sub-types and immune cell populations in canine intestines: Evidence for age-related decline in T cells and macrophages and increase of IgA-positive plasma cells. Res Vet Sci 2008;84:41–48.

37. Geyman JP, Deyo RA, Ramsey SD. Evidence-Based Clinical Practice: Concepts and Approaches. Woburn, MA: Butterworth/Heinemann; 2000.

38. Hall EJ, Batt RM Development of wheat-sensitive enteropathy in Irish Setters: Morphologic changes. Am J Vet Res 1990;51:978–982.

39. Paulsen DB, Buddington KK, Buddington RK. Dimensions and histologic characteristics of the small intestine of dogs during postnatal development. Am J Vet Res 2003;64:618–626.

40. Roth L, Walton AM, Leib MS. Plasma cell populations in the colonic mucosa of clinically normal dogs. J Am Anim Hosp Assoc 1992;28:39–42.

41. Kolbjørnsen Ø, Press CM, Moore PF, Landsverk T. Lymphoid follicles in the gastric mucosa of dogs. Distribution and lymphocyte phenotypes. Vet Immun Immunopath 1994;40:299–312.

42. Elwood CM, Hamblin AS, Batt RM. Quantitative and qualitative immunohistochemistry of T cell subsets and MHC Class II expression in the canine small intestine. V Immun Immunopath 1997;58:195–207.

43. German AJ, Hall EJ, Day MJ. Analysis of leucocyte subsets in the canine intestine. J Comp Path 1999;120:129–145.

44. German AJ, Hall EJ, Kelly DF, et al. An immunohistochemical study of histiocytic ulcerative colitis in boxer dogs. J Comp Path 2000;122:163–175.

45. Sonea IM, Harkins K, Wannemuehler MJ, et al. Flow cytometric analysis of canine colonic mucosal lymphocytes from endoscopically obtained biopsy specimens. Am J Vet Res 1999;60: 346–353.

46. Roccabianca P, Woo JC, Moore PF. Characterization of the diffuse mucosal associated lymphoid tissue of feline small intestine. V Immun Immunopath 2000;75:27–42.

47. Waly N, Gruffydd-Jones TJ, Stokes CR, et al. The distribution of leucocyte subsets in the small intestine of normal cats. J Comp Path 2001;124:172–182.

48. Southorn EP. An Improved Approach to the Histologic Assessment of Canine Chronic Gastritis. Guelph, Ontario: University of Guelph; 2004. DVSc Thesis.

49. Janeczko S, Atwater D, Bogel E, et al. The relationship of mucosal bacteria to duodenal histopathology, cytokine mRNA, and clinical disease activity in cats with inflammatory bowel disease. Vet Micro 2008;128:178–193.

50. Hart IR, Kidder DE. The quantitative assessment of normal canine small intestinal mucosa. Res Vet Sci 1978;25:157–162.

51. Konno A, Hashimoto Y, Kon Y, Sugimura M. Perforin-like immunoreactivity in feline globule leukocytes and their distribution. J Vet Med Sci 1994;56:1101–1105.

52. Simpson KW, Dogan B, Rishniw M, et al. Adherent and invasive *Escherichia coli* is associated with granulomatous colitis in Boxer dogs. Infect Immun 2006;74:4778–4792.

53. Casamian-Sorrosal D, Willard MD, Murray JK, et al. Comparison of histopathologic findings in biopsies from the duodenum and ileum of dogs with enteropathy. J Vet Intern Med 2010; 24:80–83.

54. Evans S, Bonczynski J, Broussard J, et al. Comparison of endoscopic and full-thickness biopsy specimens for diagnosis of inflammatory bowel disease and alimentary tract lymphoma in cats. J Am Vet Med Assoc 2006;229:1447–1450.

19391676, 2010, 1, Downloaded from https://onlinelibrary.wiley.com/doi/10.1111/j.1939-1676.2009.0443.x, Wiley Online Library on [01/11/2025]. See the Terms and Conditions (https://onlinelibrary.wiley.com/terms-and-conditions) on Wiley Online Library for rules of use; OA articles are governed by the applicable Creative Commons License

55. Padda S, Shah I, Ramirez FC. Adequacy of mucosal sampling with the two-bite forceps technique: A prospective, randomized, blinded study. Gastro Endo 2003;57:170–173.

56. Fantin AC, Neuweiler J, Binek JS, et al. Diagnostic quality of biopsy specimens: Comparison between a conventional biopsy forceps and multi-bite forceps. Gastro Endo 2001;54:600–604.

57. Yang R, Ng S, Nichol M, et al. A cost and performance evaluation of disposable and re-useable biopsy forceps in G.I. endoscopy. Gastro Endo 2000;51:266–270.

58. Woods KL, Anand BS, Cole R, et al. Influence of endoscopic biopsy forceps characteristics on tissue specimens: Results of a prospective randomized study. Gastro Endo 1999;49:177–183.

59. Danesh BJZ, Burke M, Newman J, et al. Comparison of weight, depth, and diagnostic adequacy of specimens obtained with 16 different biopsy forceps designed for upper gastrointestinal endoscopy. Gut 1985;26:227–231.

60. Mansell JM, Willard MD. Biopsy of the gastrointestinal tract. Vet Clin N Am 2003;33:1099–1116.

61. Jergens AE, Moore FM. Endoscopic biopsy specimen collection and histopathologic considerations. In: Tams T, ed. Small Animal Endoscopy. St Louis, MO: Mosby Yearbook; 1999: 323–340.

62. Guilford WG. Upper gastrointestinal endoscopy. In: McCarthy T, ed. Veterinary Endoscopy for the Small Animal Practitioner. St Louis, MO: Elsevier; 2005: 279–321.

63. Willard MD, Lovering SL, Cohen ND, Weeks BR. Quality of tissue specimens obtained endoscopically from the duodenum of dogs and cats. J Am Vet Med Assoc 2001;219:474–9.

64. Jacobs G, Collins-Kelly L, Lappin M, et al. Lymphocytic-plasmacytic enteritis in 24 dogs. J Vet Intern Med 1990;4:45–53.

65. Ridyard AE, Nuttall TJ, Else RW, et al. Evaluation of Th1, Th2 and immunosuppressive cytokine mRNA expression within the colonic mucosa of dogs with idiopathic lymphocytic plasmacytic colitis. Vet Immunol Immunopathol 2002;86:205–214.

66. Crandell JM, Jergens AE, Morrison JA, et al. Development of a clinical scoring index for disease activity in feline inflammatory bowel disease. J Vet Intern Med 2006;20:788–789.

67. Allenspach K, Rufenacht S, Sauter S, et al. Pharmacokinetics and clinical efficacy of cyclosporine treatment of dogs with steroid-refractory inflammatory bowel disease. J Vet Intern Med 2006;20:239–244.

68. Willard MD, Moore GE, Denton BD, et al. Effect of tissue processing on assessment of endoscopic intestinal biopsies in dogs and cats. J Vet Intern Med 2010;24:84–89.

69. Washabau RJ, Holt DE. Diseases of the large intestine. In: Ettinger SJ, Feldman EC, eds. Textbook of Veterinary Internal Medicine, 6th ed. Philadelphia, PA: WB Saunders Co; 2005:1378–1408.

70. Rudorf H, van Schaik G, O'Brien RT, et al. Ultrasonographic evaluation of the thickness of the small intestinal wall in dogs with inflammatory bowel disease. J Small Anim Pract 2005;46: 322–326.

71. Gaschen L, Kircher P, Stussi A, et al. Comparison of ultrasonographic findings with clinical activity index (CIBDAI) and diagnosis in dogs with chronic enteropathies. Vet Rad Ultrasound 2008;49:56–64.

72. Sutherland-Smith J, Penninck DG, Keating JH, Webster CRL. Ultrasonographic intestinal hyperechoic mucosal striation in dogs are associated with lacteal dilatation. Vet Radiol Ultra 2007;48:51–57.

73. Nguyen Van N, Taglinger K, Helps CR, et al. Measurement of cytokine mRNA expression in intestinal biopsies of cats with inflammatory enteropathy using quantitative real-time RT-PCR. Vet Immunol Immunopathol 2006;113:404–414.

74. Cho JH, Weaver CT. The genetics of inflammatory bowel disease. Gastroenterology 2007;133:1327–1339.

75. Meresse B, Ripoche J, Heyman M, Cerf-Bensussan N. Celiac disease: From oral tolerance to intestinal inflammation, autoimmunity and lymphomagenesis. Mucos Immunol 2009;2:8–23.

76. Bridgeford EC, Marini RP, Fengy Y, et al. Gastric *Helicobacter* species as a cause of feline gastric lymphoma: A viable hypothesis. Vet Immunol Immunopathol 2008;123:106–113.

77. Jones JL, Loftus EV. Lymphoma risk in inflammatory bowel disease: Is it the disease or the treatment? Inflamm Bowel Dis 2007;13:1299–1307.

78. Louwerens M, London CA, Pedersen NC, et al. Feline lymphoma in the post-feline leukemia virus era. J Vet Intern Med 2005;19:329–335.

79. Pohlman LM, Higginbottom ML, Welles EG, Johnson CM. Immunophenotypic and histologic classification of 50 cases of feline gastrointestinal lymphoma. Vet Pathol 2009;46:259–268.

80. Waly NE, Gruffydd-Jones TJ, Stokes CR, Day MJ. Immunohistochemical diagnosis of alimentary lymphomas and severe intestinal inflammation in cats. J Comp Pathol 2005;133: 254–260.

81. Moore PF, Woo JC, Vernau W, et al. Characterization of feline T cell receptor gamma (TCRG) variable region genes for the molecular diagnosis of feline intestinal T cell lymphoma. Vet Immunol Immunopathol 2005;106:167–178.

82. Simpson KW. Diseases of the stomach. In: Ettinger S, Feldman E, eds. Textbook of Veterinary Internal Medicine, 6th ed. Philadelphia, PA: Elsevier; 2005:1310–1331.

83. Leib MS, Duncan RB, Ward DL. Triple antimicrobial therapy and acid suppression in dogs with chronic vomiting and gastric *Helicobacter* spp. J Vet Intern Med 2007;21:1185–1192.

84. Neiger R, Simpson KW. Helicobacter infection in dogs and cats: Facts and fiction. J Vet Intern Med 2000;14:125–133.

85. Simpson K, Neiger R, DeNovo R, et al. The relationship of Helicobacter spp. infection to gastric disease in dogs and cats (ACVIM Consensus Statement). J Vet Intern Med 2000;14:223–227.

86. Priestnall SL, Wiinberg B, Spohr A, et al. Evaluation of "Helicobacter heilmannii" subtypes in the gastric mucosas of cats and dogs. J Clin Microbiol 2004;42:2144–2155.

87. Elwood C. Best practice for small intestinal biopsy. J Small Anim Prac 2005;46:315–316.

88. Price AB. The Sydney system: Histological division. J Gastro Hepatol 1991;6:209–222.

89. Dixon MF, Genta RM, Yardley JH, Correa P. Classification and grading of gastritis, the updated Sydney system. International workshop on the histopathology of gastritis. Am J Surg Pathol 1996;20:1161–1181.

90. Drossman DA. The functional gastrointestinal disorders and the Rome III process. Gastroenterology 2006;130:1377–1390.

91. Drossman DA, Dumitrascu DL. Rome III: New standard for functional gastrointestinal disorders. J Gastrointestin Liver Dis 2006;15:237–241.

19391676, 2010, 1, Downloaded from https://onlinelibrary.wiley.com/doi/10.1111/j.1939-1676.2009.0443.x, Wiley Online Library on [01/11/2025]. See the Terms and Conditions (https://onlinelibrary.wiley.com/terms-and-conditions) on Wiley Online Library for rules of use; OA articles are governed by the applicable Creative Commons License

Appendix 1

Standard reporting form for assessment of the duodenal mucosa. Reprinted with permission.[3]

Histopathologic Guidelines for the Diagnosis of Idiopathic Inflammatory Bowel Diseases in Dogs and Cats

Standard Form for Assessment of Duodenal Mucosa

Pathologist _____ Case Number _____
Number of pieces of duodenal tissue on slide _____
Tissue present: _____ inadequate _____ too superficial _____ adequate depth
Number of tissues abnormal: _____

Morphological Features	Normal	Mild	Moderate	Marked
Villous Stunting	□	□	□	□
Epithelial Injury	□	□	□	□
Crypt Distension	□	□	□	□
Lacteal Dilation	□	□	□	□
Mucosal Fibrosis	□	□	□	□

Inflammation	Normal	Mild	Moderate	Marked
Intraepithelial Lymphocytes	□	□	□	□
Lamina Propria Lymphocytes	□	□	□	□
Lamina Propria Neutrophils	□	□	□	□
Lamina Propria Eosinophils	□	□	□	□

Final Diagnosis: _____ Other Comments: _____

Appendix 2

Standard reporting form for assessment of the colonic mucosa. Reprinted with permission.[3]

Histopathologic Guidelines for the Diagnosis of Idiopathic Inflammatory Bowel Diseases in Dogs and Cats

Standard Form for Assessment of Colonic Mucosa

Pathologist _____ Case Number _____
Number of pieces of colonic tissue on slide _____
Tissue present: _____ inadequate _____ too superficial _____ adequate depth
Number of tissues abnormal: _____

Morphological Features	Normal	Mild	Moderate	Marked
Surface Epithelial Injury	□	□	□	□
Crypt Hyperplasia	□	□	□	□
Crypt Dilation/Distortion	□	□	□	□
Fibrosis/Atrophy	□	□	□	□

Inflammation	Normal	Mild	Moderate	Marked
Lamina Propria Lymphocytes	□	□	□	□
Lamina Propria Neutrophils	□	□	□	□
Lamina Propria Eosinophils	□	□	□	□
Lamina Propria Macrophages	□	□	□	□

Final Diagnosis: _____ Other Comments: _____

19391676, 2010, 1, Downloaded from https://onlinelibrary.wiley.com/doi/10.1111/j.1939-1676.2009.0443.x, Wiley Online Library on [01/11/2025]. See the Terms and Conditions (https://onlinelibrary.wiley.com/terms-and-conditions) on Wiley Online Library for rules of use; OA articles are governed by the applicable Creative Commons License

Appendix 3

Standardized report form for upper gastrointestinal endoscopy. Reprinted with permission.[1]

ENDOSCOPIC EXAMINATION REPORT: UPPER GI ENDOSCOPY

Date of procedure: ..... **Case Number:** .....

Patient and client information:
(card or stamp)

PROCEDURE(S): _____
Indication(s) for procedure: _____
Endoscope(s) used: _____
Forceps/retrieval device(s) used: _____

PROBLEMS/COMPLICATIONS: None ☐
Perforation ☐ Excessive bleeding ☐ Anesthetic complications ☐ Excessive time ☐ Other ☐
Comments: _____
☐ Unable to complete full examination: why? _____
☐ Unable to obtain adequate biopsies: why? _____
☐ Unable to retrieve foreign object: why? _____
☐ Visualization obscured why? _____

SAMPLING: Biopsy ☐ Brush cytology ☐ Washing ☐ Aspiration ☐ Foreign body retrieved ☐

DOCUMENTATION: Video ☐ Photographs ☐

ESOPHAGUS Normal ☐ Foreign body ☐ Mass ☐ Stricture ☐ Hiatal hernia ☐

Lesion	Code	Comments (include location)
Hyperemia/vascularity		
Discoloration		
Friability		
Hemorrhage		
Erosion/ulcer		
Contents (mucus/bile/food)		
Dilation		
Gastroesophageal sphincter		
Other		

Code: Normal = 0 Mild = 1 Moderate = 2 Severe = 3

19391676, 2010, 1, Downloaded from https://onlinelibrary.wiley.com/doi/10.1111/j.1939-1676.2009.0443.x, Wiley Online Library on [01/11/2025]. See the Terms and Conditions (https://onlinelibrary.wiley.com/terms-and-conditions) on Wiley Online Library for rules of use; OA articles are governed by the applicable Creative Commons License

STOMACH Normal ☐ Foreign body ☐ Mass ☐ Polyp(s) ☐ Parasite(s) ☐

Site(s) of lesions: Fundus ☐ Body ☐ Incisura ☐ Antrum ☐ Pylorus ☐

Site(s) of biopsies: Fundus ☐ Body ☐ Incisura ☐ Antrum ☐ Pylorus ☐

Lesion	Code	Comments (include location)
Can't inflate lumen		
Hyperemia/vascularity		
Edema		
Discoloration		
Friability		
Hemorrhage		
Erosion/ulcer		
Contents (mucus/bile/food)		
Gastroesophageal sphincter		
Passing scope through pylorus		
Other		

DUODENUM/JEJUNUM Normal ☐ Foreign body ☐ Mass ☐ Polyp ☐ Parasite(s) ☐

How far was the tip of the scope advanced?_____

Was/were the papilla(e) seen? Yes ☐ (which? _____) No ☐

Lesion	Code	Comments (include location)
Can't inflate lumen		
Hyperemia/vascularity		
Edema		
Discoloration		
Friability		
Texture		
Hemorrhage		
Erosion/ulcer		
Lacteal dilatation		
Contents (mucus/bile/food)		
Other		

Code: Normal = 0 Mild = 1 Moderate = 2 Severe = 3

Comments and Recommendations: _____

_____

_____

Endoscopist signature _____

This standard form was developed by the WSAVA Gastrointestinal Standardization Group (Drs Washabau, Willard, Hall, Jergens, Day, Mansell, Wilcox, Minami, Guilford, and Biltzer) with sponsorship from Hill's Pet Nutrition

19391676, 2010, 1, Downloaded from https://onlinelibrary.wiley.com/doi/10.1111/j.1939-1676.2009.0443.x, Wiley Online Library on [01/11/2025]. See the Terms and Conditions (https://onlinelibrary.wiley.com/terms-and-conditions) on Wiley Online Library for rules of use; OA articles are governed by the applicable Creative Commons License

Appendix 4

Standardized report form for lower gastrointestinal endoscopy. Reprinted with permission.[1]

ENDOSCOPIC EXAMINATION REPORT: LOWER GI ENDOSCOPY

Date of procedure: ..... **Case Number:** .....

Patient and client information:
(card or stamp)

PROCEDURE(S): _____
Indication(s) for procedure: _____
Endoscope(s) used: _____
Forceps used: _____
Method of preparing colon: _____

PROBLEMS/COMPLICATIONS: None ☐ Colonic preparation inadequate ☐
Perforation ☐ Excessive bleeding ☐ Anesthetic complications ☐ Excessive time ☐ Other ☐
Comments: _____
☐ Unable to complete full examination: why? _____
☐ Unable to obtain adequate biopsies: why? _____
☐ Visualization obscured why? _____

SAMPLING: Biopsy ☐ Brush cytology ☐ Washing ☐ Aspiration ☐
DOCUMENTATION: Video ☐ Photographs ☐

COLON Normal ☐ Foreign body ☐ Parasite(s) ☐ Mass ☐ Polyp ☐
Visualized: ileo-colic valve ☐ ceco-colic valve (dog) ☐ cecum (cat) ☐
If did not see ileo-colic valve area, how far was the scope advanced ? _____

Lesion	Code	Comments (include location)	
Hyperemia/vascularity			
Discoloration			
Friability /Hemorrhage			
Erosion/ulcer			
Intussusception			
Stricture			
Artifact			
Other			

Code: Normal = 0 Mild = 1 Moderate = 2 Severe = 3

19391676, 2010, 1, Downloaded from https://onlinelibrary.wiley.com/doi/10.1111/j.1939-1676.2009.0443.x, Wiley Online Library on [01/11/2025]. See the Terms and Conditions (https://onlinelibrary.wiley.com/terms-and-conditions) on Wiley Online Library for rules of use; OA articles are governed by the applicable Creative Commons License

ILEUM **NOT EXAMINED** ☐

☐ Tried to pass scope through ileocolic valve: Successful ☐ Unsuccessful ☐

☐ Tried to biopsy the ileum: Successful ☐ Unsuccessful ☐

Biopsies taken by: Direct visualization ☐ Blindly passing forceps through ileocolic valve ☐

Normal ☐ Foreign body ☐ Parasite(s) ☐ Mass ☐

Lesion	Code	Comments (include location)
Can't inflate lumen		
Hyperemia/vascularity		
Edema		
Discoloration		
Friability/Hemorrhage		
Erosion/ulcer		
Lacteal dilatation		
Texture of mucosa		
Mass		
Other		

CECUM **NOT EXAMINED** ☐

☐ Tried to intubate the cecum (dogs): Successful ☐ Unsuccessful ☐

Normal ☐ Foreign body ☐ Parasite(s) ☐ Mass ☐

Lesion	Code	Comments (include location)
Can't inflate lumen		
Hyperemia/vascularity		
Edema		
Discoloration		
Friability/Hemorrhage		
Texture		
Erosion/ulcer		
Other		

Code: Normal = 0 Mild = 1 Moderate = 2 Severe = 3

Comments and Recommendations: _____

_____

_____

_____

_____

Endoscopist signature _____

This standard form was developed by the WSAVA Gastrointestinal Standardization Group (Drs Washabau, Willard, Hall, Jergens, Day, Mansell, Wilcox, Minami, Guilford, and Biltzer) with sponsorship from Hill's Pet Nutrition

19391676, 2010, 1, Downloaded from https://onlinelibrary.wiley.com/doi/10.1111/j.1939-1676.2009.0443.x, Wiley Online Library on [01/11/2025]. See the Terms and Conditions (https://onlinelibrary.wiley.com/terms-and-conditions) on Wiley Online Library for rules of use; OA articles are governed by the applicable Creative Commons License